

“When it’s all in a twist” Stallion emergencies

Babiche Heil, DVM, MS
Diplomate American College Theriogenologists

UC DAVIS
VETERINARY MEDICINE

EXCEPTIONAL CARE, EDUCATION *and* INNOVATION

1

Content

- **Anatomy reproductive tract stallion**
- **Penile injury**
 - Lacerations
 - Hematoma
 - Paraphimosis
- **Scrotal edema and/or enlargement**
 - General clinical approach and consequences
- **Testicular hematoma**
- **Hematocoele/hydrocoete**
- **Testicular torsion**
- **Inguinal or scrotal hernia**



UC DAVIS
VETERINARY MEDICINE

2

Aim

Feel comfortable attending, diagnosing and treating stallion emergencies

UC DAVIS
VETERINARY MEDICINE

3

Aim

Feel comfortable attending, diagnosing and treating stallion emergencies



UC DAVIS
VETERINARY MEDICINE

4

Aim

Feel comfortable attending, diagnosing and treating stallion emergencies

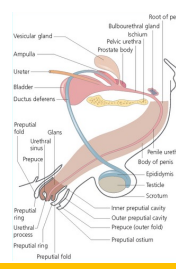


UC DAVIS
VETERINARY MEDICINE

5

Anatomy of the reproductive tract

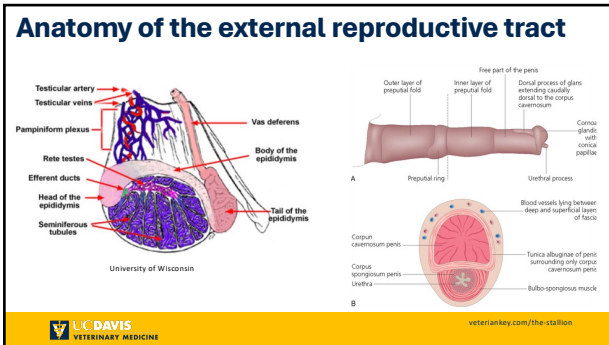
- External reproductive tract
- Internal reproductive tract



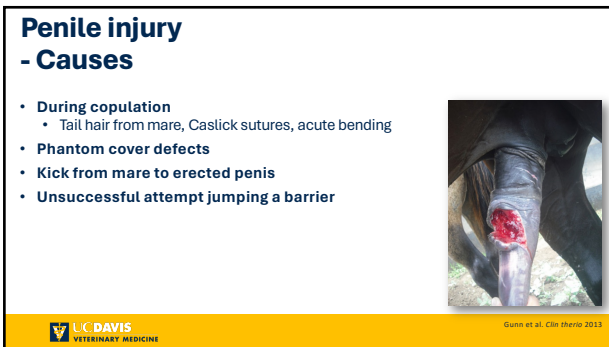
UC DAVIS
VETERINARY MEDICINE

veteriankey.com/the-stallion

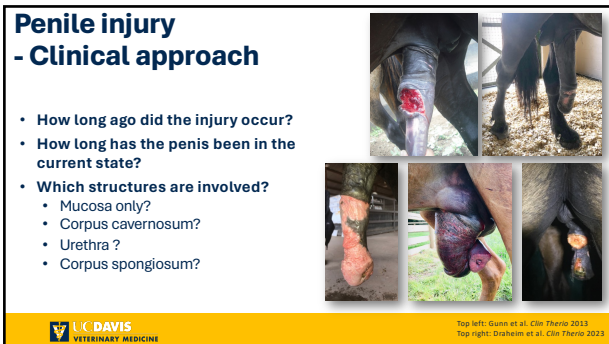6



7




8



9

Penile injury - Differential diagnosis

- **Penile laceration**
 - True laceration?
 - Harbronema?
 - Squamous cell carcinoma?
- **Penile hematoma**
 - Tear in subfascial vascular plexus
 - Tear in tunica albuginea and/or corpus cavernosum or spongiosum
- **Paraphimosis**
 - As complication of what?



UC DAVIS
VETERINARY MEDICINE

10


Penile laceration - wound management

Goal: minimize hemorrhage and edema

Treatment depends on tissue involved

- Wound?
 - Debride, flush and suture
- Infected laceration?
 - Clean and apply ointment several times per day until delayed primary closure is possible

Think ahead: a transverse urethral laceration is likely to form stricture when allowed to heal by second intention.



UC DAVIS
VETERINARY MEDICINE

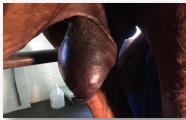
Bottom: Gunn et al. Clin Therio 2013

11

Penile hematoma - diagnosis and management

Goal: identify origin, minimize hemorrhage and edema

- Ultrasound of the penis to identify structures involved
- Massage and compression
- Drainage and flush with heparin solution



UC DAVIS
VETERINARY MEDICINE

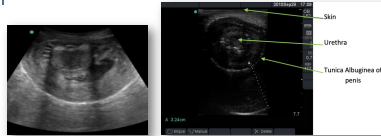
Fancio, Goni, Daglielminetti, J Vet St Tech, 2016

12

Penile hematoma - diagnosis and management

Goal: identify origin, minimize hemorrhage and edema

- Ultrasound of the penis to identify structures involved
- Massage and compression
- Drainage and flush with heparin solution



Left: Adapted from: Funck, Goni, Guglielminetti, J Vet Sci Tech, 2015
Right: Gunn et al. Clin Therio 2013

UC DAVIS
VETERINARY MEDICINE

13

Penile laceration and hematoma - Management

No arousal, and sexual rest

- **Duration depends on abnormality diagnosed**
 - Laceration: rest until fully healed
 - Hematoma:
 - 1-week complete rest to prevent hematoma filling up again
 - Arousal after 1 week is unlikely to hemorrhage again and may prevent adhesion formation.
- **Exercise: once active hemorrhage has seized**


UC DAVIS
VETERINARY MEDICINE

14

Paraphimosis

The inability to retract the penis into the preputial cavity

- Edema of prepuce/penis caused by balanoposthitis can quickly turn into paraphimosis



Bottom: Gunn et al. Clin Therio 2013


UC DAVIS
VETERINARY MEDICINE

15

Paraphimosis

- Causes

- Trauma
- Administration of phenothiazine tranquilizer (acepromazine)
- Secondary to penile paralysis
 - Very poor body condition
 - EHV-1
 - Priapism
- Secondary to severe ventral/preputial edema
 - Post laparotomy
 - Purpura hemorrhagica
 - Dourine

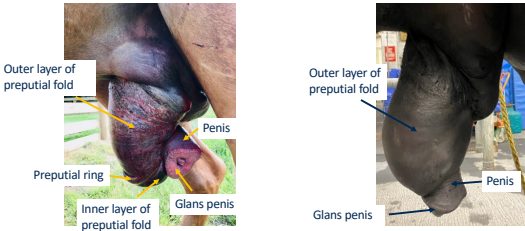


UC DAVIS VETERINARY MEDICINE
Brouwer et al. Equine Vet. Educ. 2017

16

Paraphimosis

- Clinical approach



Outer layer of preputial fold
Penis
Preputial ring
Inner layer of preputial fold
Glans penis

Outer layer of preputial fold
Penis
Glans penis

UC DAVIS VETERINARY MEDICINE

17

Paraphimosis

- Treatment

Goal: resolve problem, reduce/eliminate preputial edema, prevention preputial trauma

- Cold water therapy
 - 15-30 min.
 - Flow along penis, NO pressure hosing
- Bandaging and massage penis and prepuce
 - Max 30 min.
- Hyperosmolaric ointment (glycerin)
- Emollient (Codd liver oil)



UC DAVIS VETERINARY MEDICINE

18

Paraphimosis - Treatment cont.

- Penile support
 - Penile sling
 - Probang
- NSAIDs
- Diuretics?



UC DAVIS VETERINARY MEDICINE
Left and top: Gunn et al. Clin therio 2013
Koch et al. AAEP 2009


19

Scrotal edema/enlargement - Causes

- Testicular hemorrhage
- Hematocele/hydrocele
- Testicular torsion
- Inguinal or scrotal hernia
- Neoplasia

often result of trauma

congenital or acquired



UC DAVIS VETERINARY MEDICINE
Morressey, Clin Tech Equine Pract., 2007

20

Scrotal edema/enlargement - General clinical approach

- Visual examination scrotum and inguinal area
 - Symmetry
 - Swelling

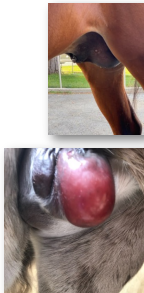


UC DAVIS VETERINARY MEDICINE

21

Scrotal edema/enlargement - General clinical approach

- Palpation scrotum, testis, spermatic cord and inguinal area
 - Pain?
 - Temperature
 - Consistency
 - Orientation and movement of the testis within the scrotum

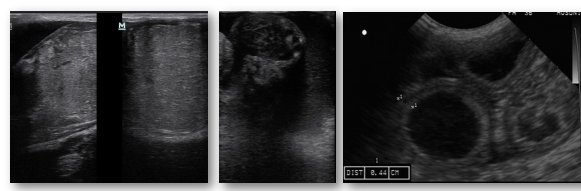


UC DAVIS VETERINARY MEDICINE
Top: Dr. P. Dine

22

Scrotal edema/enlargement - General clinical approach

- Ultrasonographic examination scrotum and testis

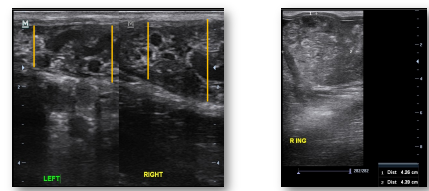


UC DAVIS VETERINARY MEDICINE
Right: Morresey, Clin Tech Equine Pract., 2007

23

Scrotal edema/enlargement - General clinical approach

- Ultrasonographic examination spermatic cord and inguinal area




UC DAVIS VETERINARY MEDICINE

24

Scrotal edema/enlargement - General consequence

- Increase of testicular temperature
- Spermatogenesis is optimal around 35°C (2-4 below BT)
- Spermatogenesis takes 57 days over 3 phases (spermatocytogenesis, meiosis and spermiogenesis) + 9 days epididymal transit
 - Spermatocytes and spermatids are most temperature sensitive

What is the effect of this temperature increase on spermatogenesis?




25

BIOLOGY OF REPRODUCTION 66, 615-620 (1999)

Scrotal Heat Stress Induces Altered Sperm Chromatin Structure Associated with a Decrease in Protamine Disulfide Bonding in the Stallion

Charles C. Love¹ and Robert M. Kenney


- Four stallions
- Insulating testis for 48 hours
- Daily sperm collection for 60 days
- Evaluation Sperm Chromatin Structure Assay (SCSA)
 - Evaluation sperm DNA integrity
 - Disulfide bonding lowers DNA susceptibility of denaturation



26

RELATIONSHIP OF PROTAMINE AND DISULFIDE LEVELS TO DNA


- Susceptibility of spermatozoal DNA depends on spermatogenic cell stage at time of thermal insult
- Increased disulfide levels increases susceptibility of DNA to denaturation



27

Pentoxifylline treatment after testicular heat insult

- Heat stress induced for 1 hour BID for two days
- 4x healthy control, 5x heat stress no Tx, 5x heat stress + Tx
- Pentoxifylline 17 mg/kg PO BID for 30 days
- Histopathology on testicular biopsy
- Gene analysis




UC DAVIS
VETERINARY MEDICINE

28

Pentoxifylline treatment after testicular heat insult

- Reduced histological damage
- No significant difference in testicular volume
- Reduction in *BAX* expression at day 30, not at day 60
- Prevention *CASP8* and *CASP9* activation
- Promotion cellular protective mechanisms through *HSF1* activation



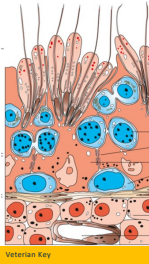
Suggestive that pentoxifylline facilitates faster recovery of testicular tissue

UC DAVIS
VETERINARY MEDICINE

29

Testicular hemorrhage

- Why an emergency?
 - Disruption of blood-testis barrier may lead to autoimmune orchitis and AntiSperm Antibody formation





UC DAVIS
VETERINARY MEDICINE

30

Testicular hemorrhage

- **Why an emergency?**
 - AntiSperm Antibodies:
 - Present in serum, seminal plasma and sperm bound
 - Decreased numbers morphologically normal sperm, immature germ cells
 - Estimated to persist for 5 years
- **Treatment**
 - Dexamethasone or prednisolone for 1-3 weeks
 - Single layer centrifugation: more ASA-free sperm


UC DAVIS VETERINARY MEDICINE Top: Select Breeder Services

31

Hematocele/hydrocele

Abnormal fluid accumulation between parietal and visceral vaginal tunic

- Due to trauma, heat stress, orchitis
- Most frequently sterile
- **Treatment**
 - Drainage blood/serous fluid is not therapeutic!
 - Hydrotherapy
 - NSAIDs
 - Diuretics
 - Orchiectomy of affected testicle
- **Prognosis for fertility: poor**

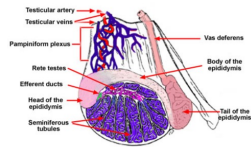


UC DAVIS VETERINARY MEDICINE

32

Testicular torsion

- **Minimal information available in the stallion**
- Torsion up to 180° is normal
- Both intra-abdominal and intra-scrotal
- All ages, all breeds
- Mild colic
- Causes testicular ischemia and tissue hypoxia




UC DAVIS VETERINARY MEDICINE Image: University of Wisconsin

33

Testicular torsion

- Minimal information available in the stallion
- Torsion up to 180° is normal
- Both intra-abdominal and intra-scrotal
- All ages, all breeds
- Mild colic
- Causes testicular ischemia and tissue hypoxia

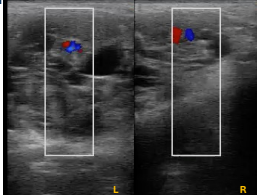


UC DAVIS VETERINARY MEDICINE Photo: Dr. Dini

34

Testicular torsion - Diagnostic approach

- Visual examination and palpation scrotum
- Location of tail of epididymis
- Ultrasonography
 - Dilation spermatic cord vessels
 - Altered testicular tissue echogenicity
 - Testicular blood supply not always altered




UC DAVIS VETERINARY MEDICINE US images: Dr. P. Dini

35

Testicular torsion - Treatment/outcome

- Human research: surgery within 4-6 hours to salvage testis
- Stallion: no data but unlikely diagnosed and corrected within 4-6 hours
- Unilateral orchidectomy
- Prognosis fertility good
 - Short term negative effect of swelling/edema on unaffected testis




UC DAVIS VETERINARY MEDICINE Video: Dr. P. Dini

36

Inguinal or scrotal hernia
- Cause

- Etiology unknown but frequently seen after alteration of abdominal pressure
 - Herniation into vaginal cavity or into fascia surrounding vaginal sac
- Venous congestion due to pressure on spermatic cord
- Hereditary?
- Adults:** intestine remain proximal to testis
- Neonate:** intestine more distally found



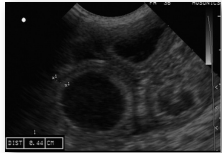
UC DAVIS
 VETERINARY MEDICINE

Top: Morresey, Clin Tech Equine Pract., 2007

37

Inguinal or scrotal hernia
- Clinical signs and diagnostic approach

- Clinical signs:**
 - Variable degree of colic
 - Firm, cold testicular swelling
- Diagnostic approach:**
 - Transcutaneous ultrasonography
 - Transrectal palpation and ultrasonography: intestine entering vaginal ring




UC DAVIS
 VETERINARY MEDICINE

Morresey, Clin Tech Equine Pract., 2007

38

Inguinal or scrotal hernia
- Treatment

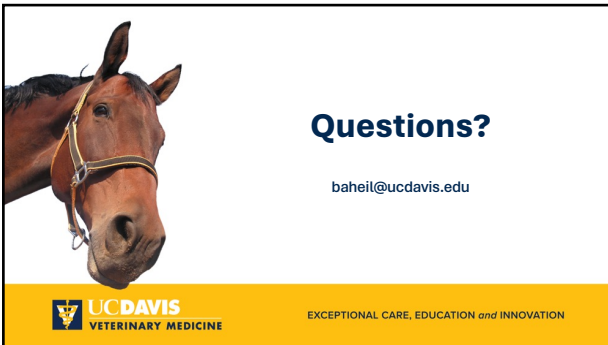- Neonates:**
 - Manual reduction, truss and confinement
- Adults and neonates:**
 - Laparotomy to reduce entrapped intestine
 - Unilateral orchidectomy and closure vaginal ring
 - Laparoscopic reduction size internal inguinal and vaginal ring



UC DAVIS
 VETERINARY MEDICINE

Saitou et al., Front. Vet. Sci., 2025

39



40